



PATIENT

Murdoch Chinn

SPECIES

Canine

BREED

Havanese

SEX

MN

AGE

13 y

WEIGHT

4.25 kg

INTERPRETED BY

Keith Blass, DVM, MS,
DACVIM (Cardiology)

IMAGING PERFORMED BY

Dr. Brian Barnes

HOSPITAL NAME

Westview VH

REFERRING VET

Dr. Barnes

INVOICE

DATE

6/9/26

PRESENTING CLINICAL SIGNS

Recheck DMVD.

ECHOCARDIOGRAPHIC FINDINGS

2D, M-mode, and Doppler study. This exam is compared to the one performed 11/13/25.

Left atrial size is normal. The mitral valve leaflets are mildly thickened, and a mild jet of eccentric mitral regurgitation is present. Left ventricular dimensions are normal. Left ventricular systolic function is normal. The aorta and aortic valve appear normal, though mild aortic insufficiency is present. Right atrial and right ventricular dimensions are normal. The tricuspid valve appears normal, though trace tricuspid regurgitation is present. The pulmonary artery and pulmonic valve appear normal, though trace pulmonic insufficiency is present. No shunting lesions are visualized. No pericardial effusion or cardiac masses are seen.

ECG during echo: Sinus arrhythmia

LA - 24.1 mm (prev. 22.4 mm)
LVIDd - 26.1 mm (prev. 24.4 mm)
LVIDs - 16.0 mm (prev. 12.2 mm)
FS - 38.7% (prev. 50%)
RA - 14.7 mm (prev. 14.6 mm)
LVOT - 1.36 m/s (prev. 1.54 m/s)
RVOT - 0.99 m/s (prev. 0.93 m/s)

ASSESSMENT/RECOMMENDATIONS

Degenerative mitral valve disease - stage B1

This examination demonstrates mild progression of Murdoch's mitral valve disease over the past 7 months. While mild progression has occurred, Murdoch still does not have secondary dilation of either of his left heart chambers. As such, his current risk for the development of clinical signs secondary to his mitral valve disease, such as coughing, exercise intolerance, syncope, and labored breathing, still appears to be low.

No therapy is recommended at this stage of disease.

A recheck echocardiogram is recommended in ~6 months.



PATIENT

Murdoch Chinn

SPECIES

Canine

BREED

Havanese

SEX

MN

AGE

13 y

WEIGHT

4.25 kg

INTERPRETED BY

Keith Blass, DVM, MS,
DACVIM (Cardiology)

IMAGING PERFORMED BY

Dr. Brian Barnes

HOSPITAL NAME

Westview VH

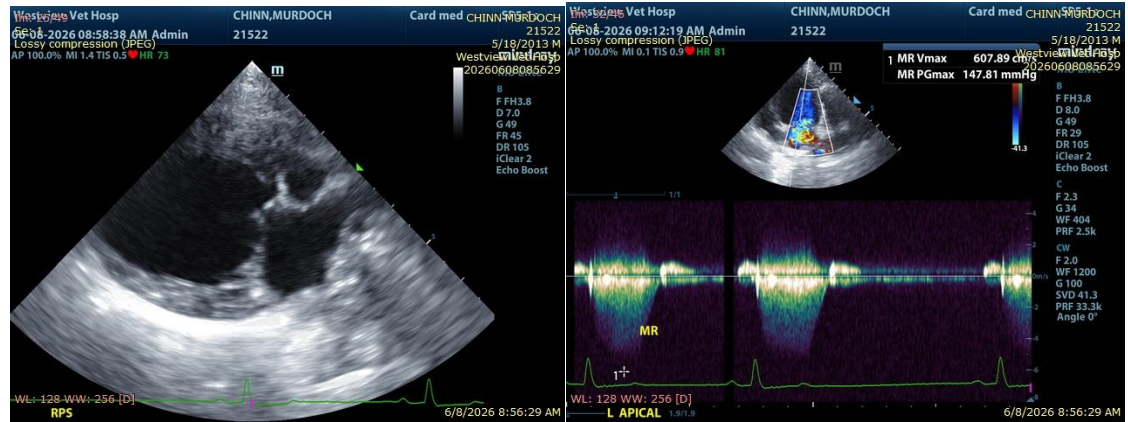
REFERRING VET

Dr. Barnes

INVOICE

DATE

6/9/26



The information and recommendations provided are based on the images presented by the referring veterinarian/sonographer. No evaluation can be communicated regarding pathology that was not visible in the image/video clips provided.

Thank you for this referral. If the clinical or image interpretation does not parallel your findings or if I can be of any further assistance please contact me.

Keith Blass, DVM, MS, DACVIM (Cardiology)

info@SonoPath.com